



Published in final edited form as:

Cancer Prev Res (Phila). 2010 July ; 3(7): 844–851. doi:10.1158/1940-6207.CAPR-09-0254.

Optical Measurement of Rectal Microvasculature as an Adjunct to Flexible Sigmoidoscopy: Gender-Specific Implications

Hemant K. Roy¹, Andrew J. Gomes², Sarah Ruderman², Laura K. Bianchi¹, Michael J. Goldberg¹, Valentina Stoyneva², Vladimir Turzhitsky^{1,2}, Young Kim³, Eugene Yen¹, Mohammed Jameel^{1,2}, Andrej Bogojevic¹, and Vadim Backman²

¹Department of Medicine, Northshore University Health System, Evanston IL 60201

²Biomedical Engineering Department, Northwestern University, Evanston IL 60201

³Biomedical Engineering Department, Purdue University, West Lafayette IN 47907

Abstract

Flexible sigmoidoscopy is a robust, clinically-validated and widely available colorectal cancer (CRC) screening technique that is currently sanctioned by both major guideline organizations. Given that endoscopic visualization is generally limited to the distal third of the colon and women tend to have a proclivity for proximal lesions, flexible sigmoidoscopy's performance is markedly inferior in women than men. Our group has demonstrated that by using a novel light scattering approach we were able to detect an early increase in blood supply (EIBS) in the distal colonic mucosa which served as a marker of field carcinogenesis and hence proximal neoplasia. Therefore, we sought to ascertain whether rectal EIBS would improve flexible sigmoidoscopy, especially in women. A polarization-gated spectroscopy fiber-optic probe was utilized to assess EIBS in the endoscopically-normal rectum (n=366). When compared to gender-matched neoplasia-free controls, females with advanced proximal neoplasia (n=10) had a robust (60%, p=0.002) increase in rectal mucosal oxyhemoglobin (OHb) content (p = 0.001) whereas the effect size in males was less marked (33%, p=0.052). In women, addition of rectal OHb tripled the sensitivity for advanced neoplasia over flexible sigmoidoscopy alone. Indeed, the performance characteristics appeared to be excellent (sensitivity=100%, specificity=76.8%, positive predictive value =32.6% and negative predictive value of 100%). A variety of non-neoplastic factors were assessed and did not confound the relationship between rectal EIBS and advanced neoplasia. Therefore, using rectal EIBS in combination with flexible sigmoidoscopy mitigated the gender-gap and may allow flexible sigmoidoscopy to be considered a viable CRC screening test in women.

Keywords

Screening; flexible sigmoidoscopy; colon cancer; adenomas; micro-circulation; gender

Correspondence: Hemant K. Roy MD, Duckworth Professor of Cancer Research, Section of Gastroenterology, NorthShore University HealthSystem, Clinical Associate Professor of Medicine, Pritzker School of Medicine, University of Chicago, Phone: 847-570-3115, Fax: 847-733-5041, h-roy@northwestern.edu.

Disclosure: Drs. Roy, Goldberg and Backman are co-founders and shareholders of American BioOptics LLC. American BioOptics LLC had no role in the design or execution of the study, data analysis or manuscript preparation. All aspects of the study and manuscript preparation were done under the supervision of the conflict of interest committee at Northwestern University.

Introduction

Colorectal cancer (CRC) remains the third leading cause of death in both women and men underscoring the need for more effective prevention strategies in both genders(1). While the lifetime incidence of CRC is roughly equivalent between women and men (5.1% versus 5.5%, respectively) there are some important distinctions(1). Biologically, lesions in women tend to have a more proximal neoplasia and a higher incidence of microsatellite instability(2). Stage-for-stage, women with CRC have a better prognosis than men(3). From a genetic/epigenetic perspective, it has been noted that specific polymorphisms can be associated with opposite effects on survival in men and women. There is also evidence that some CRC risk factors may also have gender-specific manifestations(4). This gender predilection appears to be mirrored in exogenous CRC risk factors such as obesity or tobacco use(5, 6). The biological basis for these gender-specific effects are incompletely elucidated although much attention has centered on sex hormones given the well-established chemopreventive efficacy of estrogen/progesterone(7) and the observation that estrogen receptor β functions as a tumor suppressor gene(8–10).

There has been emerging interest in understanding the implications of gender on CRC screening strategies. One of the most salient consequences of gender on colon carcinogenesis is the predilection towards proximal neoplasia in women(6). In a landmark report, Schoenfeld and colleagues noted that while flexible sigmoidoscopy detected two-thirds of advanced neoplasia in men, it only detected one-third in women(11). These concerns over performance, especially in women, have meant that flexible sigmoidoscopy has by and large been eschewed for colorectal cancer screening among Americans. However, flexible sigmoidoscopy has numerous attractive features including cost, availability (performed by primary care providers) and patient acceptability underscoring need to improve this test. Indeed, flexible sigmoidoscopy remains one of only two tests currently recommended by both major guidelines for colorectal adenoma/carcinoma screening(12, 13).

Flexible sigmoidoscopy can provide some insight into the risk of proximal neoplasia via identification of field carcinogenesis. Field carcinogenesis (also known as field cancerization, field effect, field defect, etc.) is the concept that the genetic/environmental milieu that leads to a focal neoplastic lesion in one area of the colon should be detectable, at least in some form, throughout the colon(4, 14). Indeed, standard clinical practice mandates a full colonoscopy if an adenoma (acting as a marker of the field effect) is detected in the distal colon(13). Unfortunately, as a marker of proximal neoplasia, the distal adenoma is quite insensitive, missing more than half of advanced proximal neoplasia(15, 16). Therefore, attention has been focused on identifying earlier events in carcinogenesis such as focal morphological lesions (aberrant crypt foci)(17) or cellular markers (apoptosis/proliferation) (18, 19) in the histologically normal distal colonic mucosa. While all these lesions correlate with proximal neoplasia, their performance characteristics are inadequate. Clearly, there is an urgent need to develop novel biomarkers from the distal colon that would be sensitive to proximal colonic lesions, thus allowing a resurgence of flexible sigmoidoscopy as a viable colorectal cancer screening technique, especially in women.

Our multidisciplinary colorectal cancer group has been focused on using advanced light scattering technologies to detect colonic field carcinogenesis. Using optical technology, four-dimensional elastically scattered light fingerprinting (4D-ELF)(20), we observed that the peri-cryptal microvascular blood content is elevated prior to occurrence of neoplasia in two experimental models of colon carcinogenesis, the azoxymethane-treated rat and the MIN (multiple intestinal neoplasia) mouse(21). We recently reported in a study of 222 patients with a novel polarization-gated spectroscopy fiber-optic probe that the

microvascular blood content was elevated in the endoscopically normal mucosa of patients harboring neoplasia(22). This phenomenon, termed early increase in blood supply (EIBS), was noted throughout the colon. Importantly, the endoscopically-normal rectal mucosa manifested elevated microvascular blood content in patients harboring advanced neoplasia, even in the proximal colon(23). We therefore hypothesized that EIBS measurements may provide a powerful adjunct to flexible sigmoidoscopy, especially in women where flexible sigmoidoscopy alone performs particularly poorly.

METHODS

Participants and acquisition of clinical data

All studies were approved and conducted under the supervision of the Institutional Review Board at NorthShore University HealthSystem (previously known as Evanston-Northwestern Healthcare). Patients undergoing colonoscopy for screening or surveillance were included in the study and these patients were unselected in order to replicate a typical screening population (age \geq 50 years or a younger age coupled with family history of CRC). Exclusion criteria included inability to give informed consent, colitis, poor preparation and failure to intubate the cecum (since the presence of a proximal adenoma would not be detected). This study comprised a total of 366 patients. At the conclusion of the withdrawal (visualization) phase for colonoscopy, the fiber-optic probe was inserted into the accessory channel of the colonoscope and the probe tip was placed in gentle contact with the rectal surface. The rectum was chosen as an ideal site for measurements because it is easily accessible and all flexible sigmoidoscopy invariably have access to the rectum despite any technical difficulties. On average, nine endoscopically normal rectal sites were selected for probe measurements, each requiring \sim 50 milliseconds. The per-patient rectal hemoglobin content was determined as the average of these individual rectal readings. All polyps found during the procedure were sent for pathological analysis and classified as benign lesions (i.e. hyperplastic polyps), non-advanced adenomas, or advanced adenomas. Advanced adenomas were defined as adenomas with size \geq 10 mm, $>$ 25% villous component, or having presence of high-grade dysplasia.

Endoscopically-compatible fiber-optic probe for measurement of microvascular blood supply

The probe design has been described in detail in recent publications (22). Briefly, we developed a polarization-gated fiber-optic probe compatible with the accessory channel of a standard or pediatric colonoscope as shown in Fig. 1(A). The probe enables measurement of the concentration of oxygenated and deoxygenated blood hemoglobin within the first 95 μ m into tissue, which roughly corresponds to the depth of the mucosa. For the first 216 patients enrolled in the study, the clinical setup utilized a 75W arc lamp and integrated CCD spectrometer described in our previous studies. For the subsequent 150 patients, we simplified the instrumentation to minimize cost and size for greater clinical applicability. This simplified clinical setup includes a white light LED (WT&T) that served as an illumination source and two fiber-optic spectrometers (Ocean Optics) for detection of light from the tissue. Data processed from the spectrometers were analyzed and displayed in real-time using a laptop computer. Hemoglobin content was extracted from the tissue signals using the algorithm described in a previous publication (22). The compact EIBS instrument is illustrated in Fig. 1 (B).

Statistical Analysis

Statistical analysis was performed using Stata 9 (StataCorp) and Microsoft Excel. Markers were compared between no neoplasia patients and advanced neoplasia patients using a two-sided Welch's t-test. A two-sided P value $<$ 0.05 was considered statistically significant. The

influence of demographic factors was found using a least squares multivariate linear regression.

Diagnostic performance for discrimination between patients without neoplasia and those patients with advanced neoplasia was assessed with logistic regression using a single marker (mucosal oxygenated Hb content). A receiver-operating-characteristic (ROC) curve was generated by plotting sensitivity and 1-specificity for the whole range of possible cutoff values. The area under the ROC curve represents the probability that the logistic regression model will give a higher predicted probability to a randomly selected positive sample versus a randomly chosen negative sample. This metric is used to summarize the overall accuracy of the logistic regression algorithm. To test the stability of the logistic regression model, leave-one-out-cross validation (LOOCV) was performed using MATLAB. LOOCV trains the algorithm on all samples except for one point that serves as the test set. The process is repeated until all samples have been tested. For each iteration, a logistic model was formed using marker values from the n-1 training samples and a predicted probability was calculated for the test point. After all iterations were completed, another ROC curve was generated using the predicted probabilities determined by the LOOCV algorithm.

Results

Patient Characteristics

We obtained readings from 366 patients undergoing colonoscopy. Of these 366 patients, 327 were Caucasian and 17 had polyps identified and removed during previous colonoscopy. Grouped by current pathological findings, 271 patients were adenoma-free, 67 had non-advanced adenomas and 28 patients with advanced neoplasia detected (defined as an advanced adenoma or colonic malignancy). After grouping by gender and location of the advanced neoplasia (distal colon was defined as rectum to splenic flexure whereas proximal colon included transverse, ascending and cecum), there were 10 female patients with advanced proximal neoplasia and 6 male patients with advanced proximal neoplasia. In addition, there were 4 female patients with advanced distal neoplasia and 8 male patients with advanced distal neoplasia. Subjects with no neoplasia had a mean age of 57 ± 12 years and 124 (45%) were females. The subjects with adenomas had a mean age of 58 ± 10 years and 22 (33%) were females, and the subjects with advanced neoplasia had a mean age of 61 ± 12 years and 14 (50%) were females. Table I summarizes the demographics for female patients with and without neoplasia. Advanced neoplasia patients had a significantly greater proportion of patients with an age greater than 55 years of age when compared to patients without neoplasia (P-value = 0.048).

Assessment of EIBS markers

We analyzed rectal mucosal hemoglobin content from patients belonging to two categories: patients without neoplasia and patients with advanced neoplasia. We demonstrated in previous studies that the penetration depth of $\sim 95 \mu\text{m}$ elicited the greatest diagnostic separation between patients with and without neoplasia (22). We therefore focused only on this depth in our analysis. In Fig. 2(A) and (B), we have compared the OHb and DHb content for patients without neoplasia and those with advanced proximal neoplasia after grouping patients by gender. Figure 2 illustrates two key findings. First, by comparing (A) and (B), we observed that the effect size was statistically significant for OHb but not for DHb. Second, Fig 2 (A) demonstrates that female patients with advanced neoplasia in the proximal colon give rise to a highly significant $\sim 60\%$ increase in rectal OHb content ($p = 0.002$), whereas the effect is muted in male patients (effect size = 33%, p -value = 0.052). For female patients without neoplasia, demographic factors did not influence rectal OHb content, as shown in Table II. These results suggest that rectal OHb content could be used as

an adjuvant to flexible sigmoidoscopy to improve detection of proximal neoplasia in women.

Performance Characteristics

After determining from Fig. 2 that rectal OHb was a promising marker for proximal neoplasia in women, we next investigated the diagnostic performance of this marker for advanced neoplasia both in the case of advanced proximal lesions only and in conjunction with flexible sigmoidoscopy for advanced lesions located anywhere in the colon. The area under the ROC curve using rectal OHb alone to predict female patients with advanced proximal neoplasia was 0.88 as shown in Fig. 3. Using the 100% sensitivity cutoff from this ROC curve yields 100% sensitivity, 76.8% specificity, 25.6% PPV, and 100% NPV. The sensitivity and NPV performance characteristics compare favorably with performance characteristics for a hypothetical flexible sigmoidoscopy calculated using our dataset, assuming that any distal adenoma finding would trigger a full colonoscopy (0% sensitivity, 91.9% specificity, 0% PPV, 92.6% NPV). These values are summarized and compared in Table III. The sensitivity of rectal EIBS also compares favorably with the <10% sensitivity for flexible sigmoidoscopy noted in literature (3). After leave-one-out cross validation, the ROC curve remained high at 0.86, indicating a robust classification. We also point out an extremely low probability of data overfitting, because only one marker (OHb) was used in this study.

We next investigated how combining both distal endoscopic findings and rectal OHb content could predict which female patients would have advanced neoplasia anywhere in the colon. This analysis simulates the clinical application of performing flexible sigmoidoscopy along with rectal blood content measurements to screen the entire colon for advanced neoplasia. The distal findings from the colonoscopy served to replicate the hypothetical findings of a flexible sigmoidoscopy procedure. In addition, for the combined test, we used only the rectal OHb findings to predict proximal lesions and we used only the distal endoscopic findings to predict the distal lesions. Since the distal endoscopic findings detect all advanced distal neoplasia, the performance characteristics of the combined test closely mirror the performance characteristics for the detection of advanced proximal neoplasia using rectal OHb content. The performance characteristics for the combined test in predicting advanced neoplasia anywhere in the colon were 100% sensitivity, 76.8% specificity, 32.6% PPV, and 100% NPV. This significantly improves the performance of flexible sigmoidoscopy alone, which had the following performance for neoplasia anywhere in the colon: 28.6 % sensitivity, 94.0 % specificity, 33.3 % PPV, and 92.6 % NPV.

Discussion

We demonstrate herein that rectal mucosal microvascular blood content assessment via polarization-gated spectroscopy allowed highly accurate discrimination of patients harboring advanced proximal neoplasia with those who were neoplasia-free. Interestingly, the effect size of rectal EIBS appeared to be greater in women than men. This is particularly significant because we confirmed that flexible sigmoidoscopy *per se* was markedly inferior in women. Importantly, the combination of rectal EIBS with flexible sigmoidoscopy leads to excellent performance characteristics in both genders. Thus, employing rectal EIBS as a biomarker was able to mitigate the gender disparities that are inherent in CRC screening with flexible sigmoidoscopy.

There is emerging evidence that gender can significantly impact upon colon carcinogenesis. For instance, in a large scale prospective randomized trial (the Women's Health Initiative), supplementation with estrogen/progesterone was noted to cause a marked (38%) reduction in colorectal cancers (7). Epidemiologically, women tend to have later onset of disease(6).

Biologically, the lesions tend to be more right sided consonant with an increased prevalence of microsatellite instability (2). There has been the recent suggestion that a higher proportion of adenomas may progress to carcinomas in women versus men(24). At a molecular level, there are a variety of genes (p53, phosphatidylinositol 3-kinase etc) that differentially expressed in colon cancers from women when compared to men(10, 25). Moreover, genetic/epigenetic alterations may be gender specific consequences as demonstrated by a report that epidermal growth factor receptor polymorphisms had opposite effects on CRC survival in men and women(4). Finally, from a risk factor perspective, gender has been shown alter the clinical manifestations of other risk CRC factors such as body mass index or tobacco smoking(5, 6).

Despite the increasing appreciation of differences between women and men in CRC biology, the most recent screening guidelines have remained gender-neutral. The recommended screening options range from the minimally invasive but poorly sensitive (e.g. fecal detection of hemoglobin or DNA mutations) to the more invasive and sensitive (e.g. colonoscopy). The fecal tests are able to detect carcinomas are insensitive to adenomas. Since the major goal of screening is cancer prevention through interruption of the adenoma-carcinoma progression, the multi-group consortium (including American Cancer Society, American Gastroenterological Association and American College of Radiology) has somewhat relegated fecal tests to second line in favor of techniques that may detect adenomas (13). Only colonoscopy and flexible sigmoidoscopy are recommended by both the multigroup consortium and US Preventive Service Task Force for CRC prevention. Colonoscopy is considered by many authorities to be the gold standard. It has high accuracy, examines the entire colonic mucosa and allows polyp removal in the same session (thus leading to cancer prevention). However, it is expensive, invasive, may be uncomfortable and carries significant risks. Furthermore the resources required (endoscopic capacity and cost) for screening the entire average risk population (>90 million Americans over age 50) appears to be prohibitive(14). With regards to gender-specific issues, the ability for colonoscopy to prevent against proximal CRCs has recently been questioned(26), which is concerning for women because of the predilection for right-sided lesions(6, 11). Indeed, a recent study indicated that women had a higher risk of developing CRC after colonoscopy (4.1% vs 2.9% men, $p < 0.001$) (27). Additionally, women tend to have longer colons in smaller abdominal cavity and more likely to have had prior abdominal/pelvic surgeries making colonoscopy more painful(28). Thus, using colonoscopy as the sole option for average-risk population screening, especially in women, may not be optimal.

Flexible sigmoidoscopy has been a stalwart of CRC screening for many decades and is sanctioned by both major guideline committees for cancer prevention. Flexible sigmoidoscopy has several advantages over colonoscopy, including a more tolerable bowel purge (a leading obstacle to undergo colonoscopy or CTC) and no need for sedation because of less discomfort. Indeed, patients preferences for flexible sigmoidoscopy appear to be equivalent to colonoscopy despite the latter's superior efficacy (29). Furthermore, unlike colonoscopy, flexible sigmoidoscopy can be performed by primary care physicians or even mid-level staff (nurse practitioner, physician's assistants) thus being well suited for population screening. The efficacy of flexible sigmoidoscopy in CRC prevention is well-established with both case control and prospective studies indicating a 80–90% risk reduction in the distal colon (30–32) although one recent study failed to show any protection over 7 years (33).

The limitations of flexible sigmoidoscopy relate to the inability to directly assess proximal neoplasia which is particularly concerning in women given predilection for right-sided CRCs. Some insight into the presence of proximal neoplasia can be gleaned from identifying field carcinogenesis, but unfortunately the sentinel adenoma is noted in less than half the

patients with advanced proximal neoplasia(16). Data from our study confirms this finding with a much lower rate in women than men (28.6% vs 57.1%). This is consistent with emerging data that even advanced adenomas may be less predictive marker of CRC in women (24). There are other precedents for biomarker accuracy for colon carcinogenesis being different in men and women such as C-reactive protein (34). Thus, not only are better biomarkers as adjuncts to flexible sigmoidoscopy urgently needed, but the gender-specific performance needs to be carefully determined.

This work builds on our initial report from a different (smaller) cohort that rectal EIBS was elevated in patients harboring advanced adenomas elsewhere in their colons(23). We have previously reported that 4D-ELF was able to detect various facets of EIBS (oxyhemoglobin, deoxyhemoglobin and packaging length scale) and we corroborated with immunoblot analysis of mucosal hemoglobin(21, 22). This phenomena was depth selective, with the maximum diagnostic information at ~ 95 μm (which was used for these studies). Moreover, for simplicity and to avoid overfitting, we used a single marker (oxyhemoglobin) in our current study. Additionally, while our previous report had shown a comparable effect size for advanced adenomas regardless of location, in this study we focused exclusively on proximal lesions based on the potential clinical application(23). Detection of distal lesions by rectal EIBS is moot because in the adjunct to flexible sigmoidoscopy, these would have been endoscopically visualized. We chose advanced adenomas because this is the best established intermediate lesions in screening studies (fecal DNA, CT colography, etc)(35, 36). Our previous study had demonstrated that rectal EIBS was not sensitive to smaller lesions(23). Fortunately, these smaller adenomas are generally of no clinical consequence since they rarely harbor advanced features and their natural history is either slow growth or actual regression(37). The novel aspect of our current study is the gender-related accentuation of rectal EIBS and the coupling of this biomarker to flexible sigmoidoscopy. Importantly, we noted that the increased performance of EIBS in women appeared to effectively mitigate the poorer gender-specific performance of flexible sigmoidoscopy(11).

The biological basis for the greater sensitivity of rectal EIBS in women was not explored in this study. There are potentially a myriad of factors involved. For instance, iNOS appears to be logical given our data on the pivotal role of nitric oxide in the pathogenesis of EIBS in the AOM-treated rat model(38). An intriguing report indicated that female rats had greater mesenteric nitric oxide production than males suggesting potential biological underpinnings for gender-specific iNOS-EIBS relationship(39). Alternatively, estrogens have been shown to impact on micro-circulation (coronary) directly or through alterations in RBC deformity(40). Since most women who develop CRC are post-menopausal (hence minimal ovarian estrogen secretion), we need to be circumspect about speculation on the role of sex hormones in EIBS. However, polyp development takes a number of years, it is probable that ovarian steroids contributed during the initiation phases. Gender may also impact upon other mediators of EIBS. For instance, the fact that smoking may independently alters EIBS(22) is particularly apropos given our report that women are more susceptible to the pro-colon carcinogenic effect of cigarettes(6). Further supporting the gender-colonic blood supply relationship is the observation that vascular endothelial growth factor (VEGF) polymorphisms had differential effects on CRC risk in men and women (41). It needs to be emphasized that these mechanistic possibilities are simply speculation and require experimental confirmation.

There are a number of limitations in the study that need to be addressed. The first is that despite the significant number of patients recruited for this study (n=366), there is a relatively small number of advanced proximal neoplasms in the female subgroup (n=10) that is consistent with an average-risk screening population. It is encouraging that the effect size was sufficient to achieve statistical significance. While overfitting is possible, these

concerns are mitigated by the use of a single biomarker (oxyhemoglobin). We plan to conduct a larger prospective validation trial to unequivocally confirm these findings. This report does not address the biological basis for gender-differences with EIBS with the possibilities discussed above being speculation and requiring experimental confirmation. On the other hand, irrespective of mechanisms, this study underscores the need to evaluate CRC biomarkers such as EIBS in a gender-specific context. Another issue is inaccuracy in endoscopic adenoma size assessment (< 10mm) although this would not bias our results (42). Finally, we used colonoscopic examination of the distal colon to replicate flexible sigmoidoscopy. This is not entirely representative of the delivery of flexible sigmoidoscopy in the community where the endoscope is typically not inserted to the splenic flexure secondary to less experienced endoscopists (primary care physicians), poorer bowel purge and lack of sedation. Moreover, in women, the depth of insertion is often significantly less than in men(43). While not really impacting upon our results presented herein, we plan to conduct a prospective studies will use more “real life” flexible sigmoidoscopy conditions.

In conclusion, we demonstrate that analysis of rectal microvascular blood content was elevated in patients harboring advanced proximal neoplasia with an effect size and hence performance characteristics superior in women than men. This is of considerable importance given that flexible sigmoidoscopy is inferior in women largely due to proximal distribution of adenomas. It is striking to note that when flexible sigmoidoscopy and rectal EIBS were combined the performance characteristics in both women and men were excellent. If validated in future studies, we envision that during a conventional flexible sigmoidoscopy, the endoscopist could also take several rectal EIBS readings (generally taking approximately ~50 milliseconds per reading). If either the flexible sigmoidoscopy (presence or distal adenoma) or rectal EIBS is positive, the patient would be referred for full colonoscopy. Further studies will be needed to validate this finding. Moreover, this work highlights the need to be cognizant of gender-selective effects when developing biomarkers for cancer screening.

Acknowledgments

The authors thank Ms. Beth Parker for excellent assistance in manuscript preparation.

Supported in part by NIH grants U01 CA111257, R01 CA128641, R33CA122017, R01 CA112315, R42CA130508, R01 EB003682, R01 CA109861, R01 CA118794, R21CA140936, R21CA141112.

Literature Cited

1. Jemal A, Siegel R, Ward E, Hao Y, Xu J, Thun MJ. Cancer statistics, 2009. *CA Cancer J Clin*. 2009 Jul-Aug;59(4):225–249. [PubMed: 19474385]
2. Iacopetta B. Are there two sides to colorectal cancer? *Int J Cancer*. 2002 Oct 10; 101(5):403–408. [PubMed: 12216066]
3. Wichmann MW, Muller C, Hornung HM, Lau-Werner U, Schildberg FW. Gender differences in long-term survival of patients with colorectal cancer. *Br J Surg*. 2001 Aug; 88(8):1092–1098. [PubMed: 11488795]
4. Bernstein C, Bernstein H, Payne CM, Dvorak K, Garewal H. Field defects in progression to gastrointestinal tract cancers. *Cancer Lett*. 2008 Feb 18; 260(1–2):1–10. [PubMed: 18164807]
5. Wolf LA, Terry PD, Potter JD, Bostick RM. Do factors related to endogenous and exogenous estrogens modify the relationship between obesity and risk of colorectal adenomas in women? *Cancer Epidemiol Biomarkers Prev*. 2007 Apr; 16(4):676–683. [PubMed: 17416757]
6. Zisman AL, Nickolov A, Brand RE, Gorchow A, Roy HK. Associations between the age at diagnosis and location of colorectal cancer and the use of alcohol and tobacco: implications for screening. *Arch Intern Med*. 2006 Mar 27; 166(6):629–634. [PubMed: 16567601]

7. Chlebowski RT, Wactawski-Wende J, Ritenbaugh C, Hubbell FA, Ascensao J, Rodabough RJ, et al. Estrogen plus progestin and colorectal cancer in postmenopausal women. *N Engl J Med*. 2004 Mar 4; 350(10):991–1004. [PubMed: 14999111]
8. Kennelly R, Kavanagh DO, Hogan AM, Winter DC. Oestrogen and the colon: potential mechanisms for cancer prevention. *Lancet Oncol*. 2008 Apr; 9(4):385–391. [PubMed: 18374292]
9. Giroux V, Lemay F, Bernatchez G, Robitaille Y, Carrier JC. Estrogen receptor beta deficiency enhances small intestinal tumorigenesis in *ApcMin/+* mice. *Int J Cancer*. 2008 Jul 15; 123(2):303–311. [PubMed: 18464259]
10. Benvenuti S, Frattini M, Arena S, Zanon C, Cappelletti V, Coradini D, et al. PIK3CA cancer mutations display gender and tissue specificity patterns. *Hum Mutat*. 2008 Feb; 29(2):284–288. [PubMed: 18022911]
11. Schoenfeld P, Cash B, Flood A, Dobhan R, Eastone J, Coyle W, et al. Colonoscopic screening of average-risk women for colorectal neoplasia. *N Engl J Med*. 2005 May 19; 352(20):2061–2068. [PubMed: 15901859]
12. Screening for colorectal cancer: U.S. Preventive Services Task Force recommendation statement. *Ann Intern Med*. 2008 Nov 4; 149(9):627–637. [PubMed: 18838716]
13. Levin B, Lieberman DA, McFarland B, Andrews KS, Brooks D, Bond J, et al. Screening and surveillance for the early detection of colorectal cancer and adenomatous polyps 2008: a joint guideline from the American Cancer Society, the US Multi-Society Task Force on Colorectal Cancer, and the American College of Radiology. *Gastroenterology*. 2008 May; 134(5):1570–1595. [PubMed: 18384785]
14. Roy HK, Backman V, Goldberg MJ. Colon cancer screening: the good, the bad, the ugly. *Arch Intern Med*. 2006 Nov 13; 166(20):2177–2179. [PubMed: 17101934]
15. Lewis JD, Ng K, Hung KE, Bilker WB, Berlin JA, Brensinger C, et al. Detection of proximal adenomatous polyps with screening sigmoidoscopy: a systematic review and meta-analysis of screening colonoscopy. *Arch Intern Med*. 2003 Feb 24; 163(4):413–420. [PubMed: 12588199]
16. Lieberman DA, Weiss DG, Bond JH, Ahnen DJ, Garewal H, Chejfec G. Use of colonoscopy to screen asymptomatic adults for colorectal cancer. Veterans Affairs Cooperative Study Group 380. *N Engl J Med*. 2000 Jul 20; 343(3):162–168. [PubMed: 10900274]
17. Takayama T, Katsuki S, Takahashi Y, Ohi M, Nojiri S, Sakamaki S, et al. Aberrant crypt foci of the colon as precursors of adenoma and cancer. *N Engl J Med*. 1998 Oct 29; 339(18):1277–1284. [PubMed: 9791143]
18. Bernstein C, Bernstein H, Garewal H, Dinning P, Jabi R, Sampliner RE, et al. A bile acid-induced apoptosis assay for colon cancer risk and associated quality control studies. *Cancer Res*. 1999 May 15; 59(10):2353–2357. [PubMed: 10344743]
19. Anti M, Marra G, Armelao F, Percesepe A, Ficarelli R, Ricciuto GM, et al. Rectal epithelial cell proliferation patterns as predictors of adenomatous colorectal polyp recurrence. *Gut*. 1993 Apr; 34(4):525–530. [PubMed: 8491402]
20. Roy HK, Liu Y, Wali RK, Kim YL, Kromine AK, Goldberg MJ, et al. Four-dimensional elastic light-scattering fingerprints as preneoplastic markers in the rat model of colon carcinogenesis. *Gastroenterology*. 2004 Apr; 126(4):1071–1081. discussion 948. [PubMed: 15057746]
21. Wali RK, Roy HK, Kim YL, Liu Y, Koetsier JL, Kunte DP, et al. Increased microvascular blood content is an early event in colon carcinogenesis. *Gut*. 2005 May; 54(5):654–660. [PubMed: 15831911]
22. Roy HK, Gomes A, Turzhitsky V, Goldberg MJ, Rogers J, Ruderman S, et al. Spectroscopic microvascular blood detection from the endoscopically normal colonic mucosa: biomarker for neoplasia risk. *Gastroenterology*. 2008 Oct; 135(4):1069–1078. [PubMed: 18722372]
23. Gomes AJ, Roy HK, Turzhitsky V, Kim Y, Rogers JD, Ruderman S, et al. Rectal mucosal microvascular blood supply increase is associated with colonic neoplasia. *Clin Cancer Res*. 2009 May 1; 15(9):3110–3117. [PubMed: 19383816]
24. Roy HK, Bianchi LK. Differences in colon adenomas and carcinomas among women and men: potential clinical implications. *JAMA*. 2009 Oct 21; 302(15):1696–1697. [PubMed: 19843905]

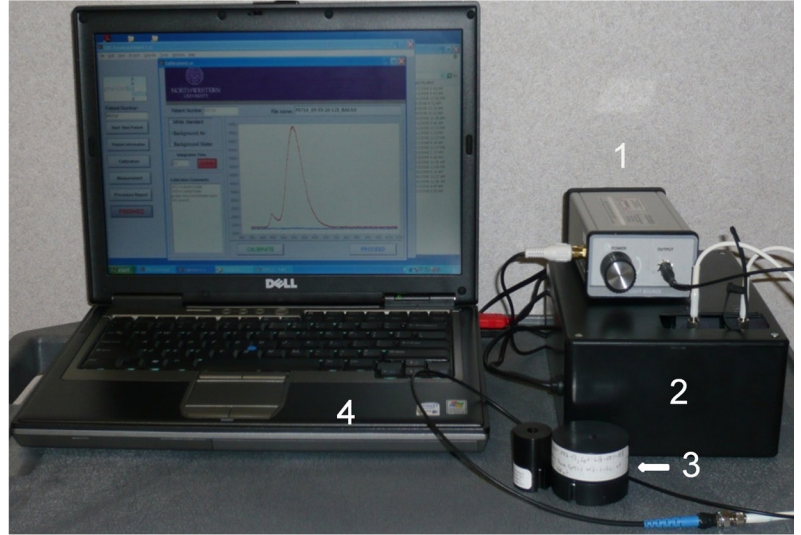
25. Slattery ML, Ballard-Barbash R, Potter JD, Ma KN, Caan BJ, Anderson K, et al. Sex-specific differences in colon cancer associated with p53 mutations. *Nutr Cancer*. 2004; 49(1):41–48. [PubMed: 15456634]
26. Baxter NN, Goldwasser MA, Paszat LF, Saskin R, Urbach DR, Rabeneck L. Association of colonoscopy and death from colorectal cancer. *Ann Intern Med*. 2009 Jan 6; 150(1):1–8. [PubMed: 19075198]
27. Singh H, Nugent Z, Mahmud SM, Demers AA, Bernstein CN. Predictors of Colorectal Cancer After Negative Colonoscopy: A Population-Based Study. *Am J Gastroenterol*. 2009 Nov 10.
28. Oh SY, Sohn CI, Sung IK, Park DI, Kang MS, Yoo TW, et al. Factors affecting the technical difficulty of colonoscopy. *Hepatogastroenterology*. 2007 Jul-Aug;54(77):1403–1406. [PubMed: 17708264]
29. Hol L, de Bekker-Grob EW, van Dam L, Donkers B, Kuipers EJ, Habbema JD, et al. Preferences for colorectal cancer screening strategies: a discrete choice experiment. *Br J Cancer*. Mar 2.
30. Newcomb PA, Zheng Y, Chia VM, Morimoto LM, Doria-Rose VP, Templeton A, et al. Estrogen plus progestin use, microsatellite instability, and the risk of colorectal cancer in women. *Cancer Res*. 2007 Aug 1; 67(15):7534–7539. [PubMed: 17671225]
31. Selby JV, Friedman GD, Quesenberry CP Jr, Weiss NS. A case-control study of screening sigmoidoscopy and mortality from colorectal cancer. *N Engl J Med*. 1992 Mar 5; 326(10):653–657. [PubMed: 1736103]
32. Thiis-Evensen E, Hoff GS, Saunar J, Langmark F, Majak BM, Vatn MH. Population-based surveillance by colonoscopy: effect on the incidence of colorectal cancer Telemark Polyp Study I. *Scand J Gastroenterol*. 1999 Apr; 34(4):414–420. [PubMed: 10365903]
33. Hoff G, Grotmol T, Skovlund E, Bretthauer M. Risk of colorectal cancer seven years after flexible sigmoidoscopy screening: randomised controlled trial. *BMJ*. 2009; 338:b1846. [PubMed: 19483252]
34. Chiu HM, Lin JT, Chen TH, Lee YC, Chiu YH, Liang JT, et al. Elevation of C-reactive protein level is associated with synchronous and advanced colorectal neoplasm in men. *Am J Gastroenterol*. 2008 Sep; 103(9):2317–2325. [PubMed: 18844617]
35. Imperiale TF, Ransohoff DF, Itzkowitz SH, Turnbull BA, Ross ME. Fecal DNA versus fecal occult blood for colorectal-cancer screening in an average-risk population. *N Engl J Med*. 2004 Dec 23; 351(26):2704–2714. [PubMed: 15616205]
36. Johnson CD, Chen MH, Toledano AY, Heiken JP, Dachman A, Kuo MD, et al. Accuracy of CT colonography for detection of large adenomas and cancers. *N Engl J Med*. 2008 Sep 18; 359(12):1207–1217. [PubMed: 18799557]
37. Hofstad B, Vatn MH, Andersen SN, Huitfeldt HS, Rognum T, Larsen S, et al. Growth of colorectal polyps: redetection and evaluation of unresected polyps for a period of three years. *Gut*. 1996 Sep; 39(3):449–456. [PubMed: 8949653]
38. Roy HK, Wali RK, Kim Y, Liu Y, Hart J, Kunte DP, et al. Inducible nitric oxide synthase (iNOS) mediates the early increase of blood supply (EIBS) in colon carcinogenesis. *FEBS Lett*. 2007 Aug 7; 581(20):3857–3862. [PubMed: 17658518]
39. Gonzales RJ, Bryant JM, Naik JS, Resta TC, Walker BR. Gender differences in mesenteric vasoconstrictor reactivity following chronic hypoxia. *Microcirculation*. 2008 Aug; 15(6):473–484. [PubMed: 19086257]
40. Sakashita T, Nobuzane T, Miyoshi H, Fujiwara H, Kudo Y. Effects of menopause and hormone therapy on erythrocyte deformability. *Menopause*. 2009 May-Jun;16(3):555–558. [PubMed: 19169165]
41. Bae SJ, Kim JW, Kang H, Hwang SG, Oh D, Kim NK. Gender-specific association between polymorphism of vascular endothelial growth factor (VEGF 936 C>T) gene and colon cancer in Korea. *Anticancer Res*. 2008 Mar-Apr;28(2B):1271–1276. [PubMed: 18505065]
42. Gopalswamy N, Shenoy VN, Choudhry U, Markert RJ, Peace N, Bhutani MS, et al. Is in vivo measurement of size of polyps during colonoscopy accurate? *Gastrointest Endosc*. 1997 Dec; 46(6):497–502. [PubMed: 9434215]

43. Eloubeidi MA, Wallace MB, Desmond R, Farraye FA. Female gender and other factors predictive of a limited screening flexible sigmoidoscopy examination for colorectal cancer. *Am J Gastroenterol.* 2003 Jul; 98(7):1634–1639. [PubMed: 12873591]

(A)



(B)

**Figure 1.**

Fiber-optic polarization-gated probe and clinical data collection system for real-time measurements *in vivo*. (A) The 2.45 mm diameter probe protruding from an accessory channel of an endoscope, (B) Photograph of the compact EIBS instrument with real-time capability for EIBS detection consisting of white light LED light source (1), fiber-optic spectrometers (2), calibration stage (3), and laptop for real-time data display and analysis (4).

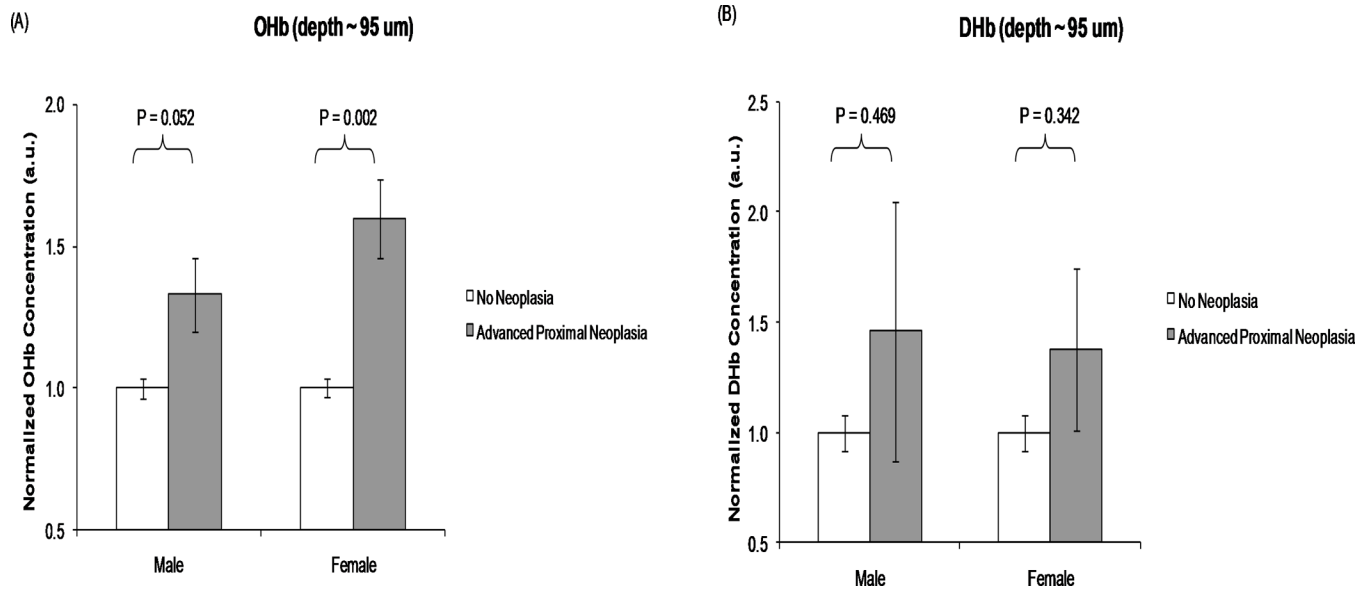


Figure 2. Rectal OHb content from a tissue depth of ~ 95 μm is significantly elevated in women with advanced proximal neoplasia. (A) OHb content was elevated for both men ($N = 6$) and women ($N = 10$) with advanced proximal neoplasia but the effect was more pronounced in women (effect size = 60%, $p = 0.002$), (B) DHb content was also elevated in men and women with advanced proximal neoplasia but the effect size was not significant. Bars, SE.

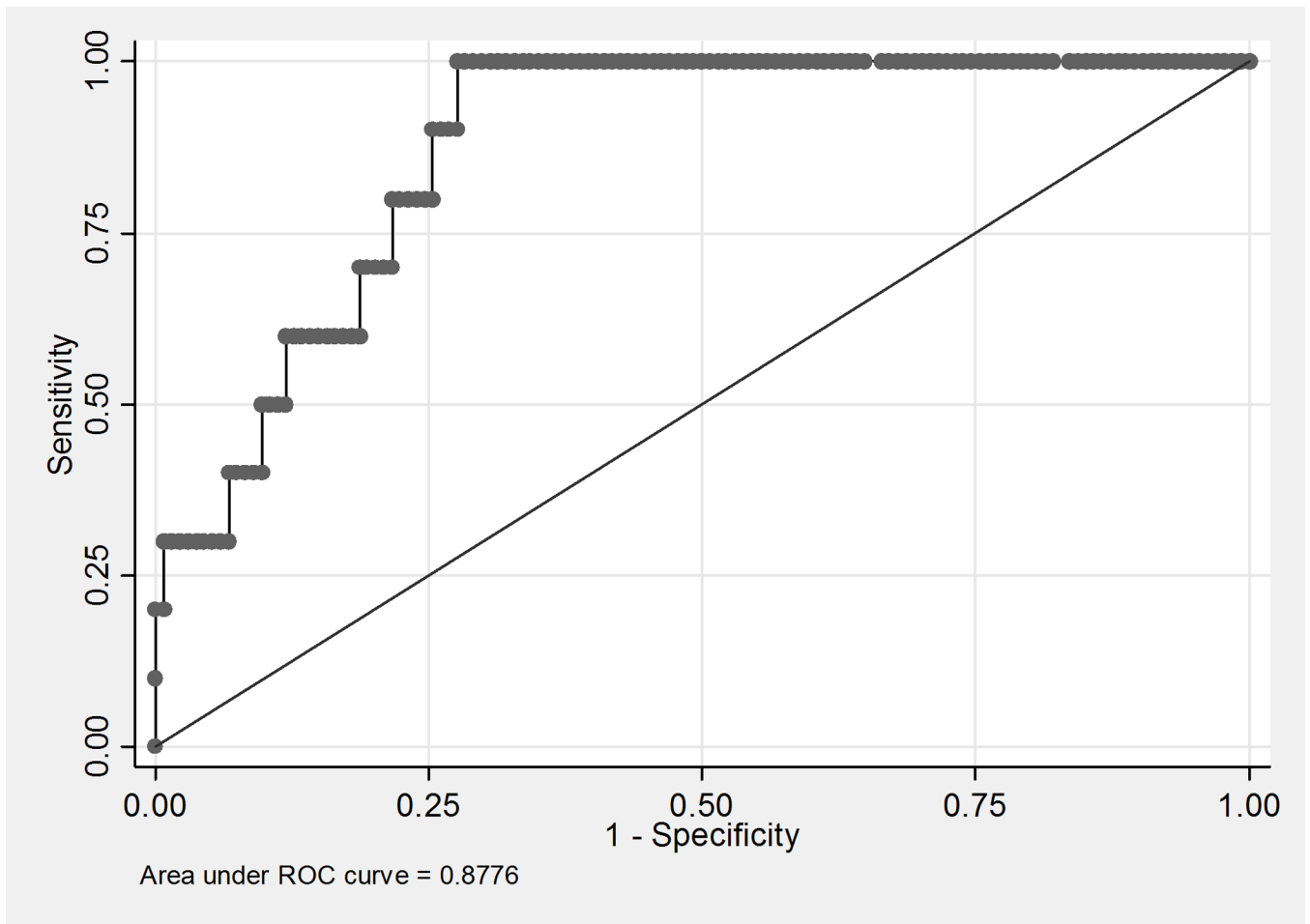


Figure 3. Receiver-operating-characteristic (ROC) curve demonstrating that measurement of rectal OHb content allows accurate prediction of advanced proximal neoplasia in women. The area under the curve is 0.88 allowing 100% sensitivity and 76.8% specificity to be obtained.

Table I

P-values for test of two proportion analysis showing differences in demographic factors between no neoplasia and disease groups.

Demographic	Adenoma	Advanced Adenoma
Age: (< 55 yrs vs. 55 yrs)	N.S.	0.048
Race: (White vs Non White)	N.S.	N.S.
Current alcohol status	N.S.	N.S.
Current smoking status	N.S.	N.S.
Personal history of polyp	N.S.	N.S.
Personal history of CRC	N.S.	N.S.
Family history of CRC	N.S.	N.S.

NOTE: N.S. indicates that P-value is not significant (> 0.05)

Table II

Multivariate linear regression ANOVA p-values showing effect of demographic factors on measured OHb in women (depth ~ 95 μm).

Demographic	ANOVA P-value
Age: (< 55 yrs vs. 55 yrs)	0.222
Race: (White vs Non White)	0.460
Current alcohol status	0.440
Current smoking status	0.850
Personal history of polyp	0.950
Personal history of CRC	0.600
Family history of CRC	0.550

NOTE: Only no neoplasia patients (n = 124) were used in the analysis

Table III

Statistical performance of predicting advanced proximal neoplasia in women using flexible sigmoidoscopy versus rectal OHb content.

Performance Characteristic	Flexible Sigmoidoscopy Only	Rectal OHb Content
Sensitivity	0%	100%
Specificity	94.3 %	76.8%
Positive Predictive Value	0%	32.6%
Negative Predictive Value	92.6%	100%